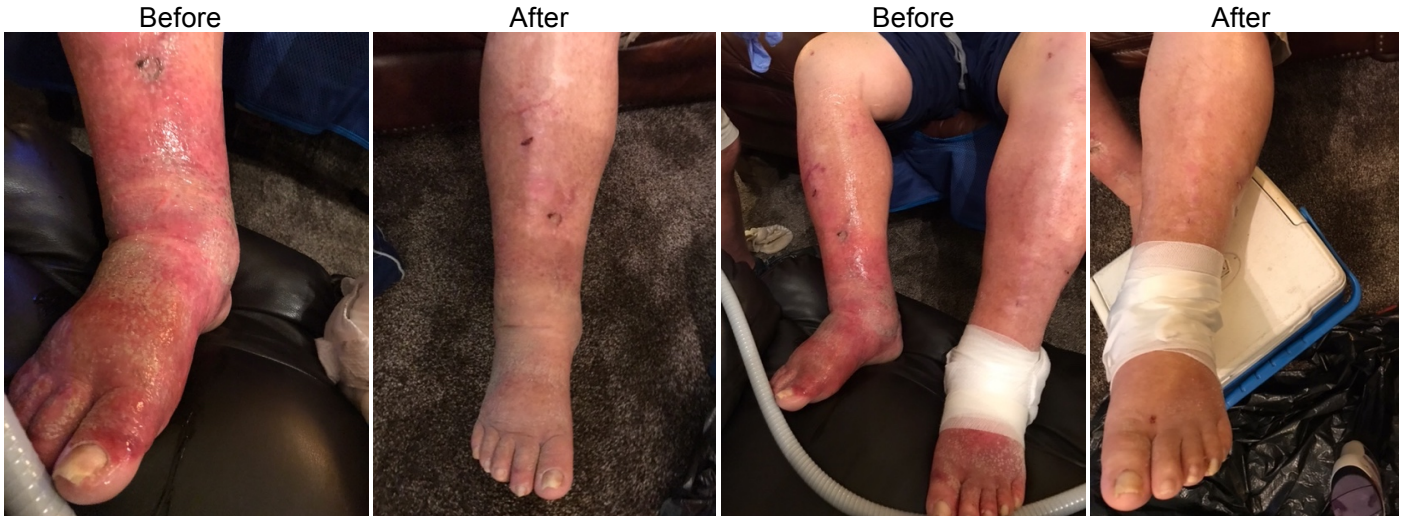


## Wound Case Study – June 2017

Tissue Regeneration Technologies, LLC

### OrthoGold 100 SoftWave Device



White male 68 5"10 300lbs uncontrolled diabetes for 12 years. Presents with severe pvd and diabetic ulcers on legs and feet. Subject can not walk is immobile. Subject has no feeling in legs or feet on both legs. Physician recommends amputation.

4000 shocks are given to each leg and foot at level 10.

Patient immediately begins to have feeling in legs and feet. Legs begin to turn pink from blood flow.

Next day the red irritation had disappeared in both legs and feet.

Subject has feelings in legs and feet.

Subject walks with crutches for first time in 6 months.

Subjects sugar levels are between a high of 124 and a low of 89. Typical levels before shock treatment were over 300.

Subject has a much improved attitude. Healing is almost complete after two weeks and subject is walking.

This is one treatment of 4000 shocks on each leg and foot one time. Physician has canceled amputation.

Before and After photos are 4 days apart.

For informational purposes only. The OrthoGold 100 is currently approved for only for pain relief.